

Fascin Expression in Oral Squamous Cell Carcinoma using an Immunohistochemical Technique

Original Article

Saede Atarbashi Moghadam¹, Zhale Mohsenifar², Ali Lotfi³, Lale Abasi⁴, Seyedeh Sara Bagheri⁵

¹ Assistant Professor, Department of Oral and Maxillofacial Pathology, Shahid Beheshti University of Medical Sciences, Tehran, Iran.

² Associate Professor, Department of Pathology, Taleghani Educational Hospital of Shahid Beheshti University of Medical Sciences, Tehran, Iran.

³ Assistant Professor, Department of Oral and Maxillofacial Pathology, Shahid Beheshti University of Medical Sciences, Tehran, Iran.

⁴ Dentist

⁵ Assistant Professor, Department of Oral and Maxillofacial Pathology, Guilan University of Medical Sciences, Rasht, Iran.

Received: Jul 22, 2015

Accepted: Aug 25, 2015

Corresponding Author:

Seyedeh Sara Bagheri

Address:

School of Dentistry, Guilan University of Medical Sciences, Rasht, Iran

Email: ssara.bagheri@gmail.com

Telephone: +981333486428

Abstract

Introduction:

Oral squamous cell carcinoma (OSCC), the most common form of oral cancer, requires early diagnosis and suitable treatments. Fascin is a protein involved in cell adhesion and is increased in expression in certain types of carcinomas. The present study was conducted to assess fascin expression in OSCC using an immunohistochemical technique.

Materials and methods:

In the present retrospective study, 25 paraffin blocks of OSCC samples were selected and immunohistochemically stained for detection of fascin expression. Fascin expression rate was calculated as the sum of stained cells (scores from 0 to 4) and staining intensity (scores from 0 to 3).

Results:

Samples collected from 18 men and 7 women, with a mean age of 57.42 years, were assessed, which showed that the most usually affected sites were the gingiva and the tongue. Fascin expression was positive for all the samples and had the highest possible score (24 cases with score 7 and 1 case with score 6). Fascin expression level was not found to have a significant relationship with age, gender, and tumor location ($P > 0.05$). The data were analyzed using SPSS statistical software (18) via chi-square analysis, independent T test and One way Anova $p < 0.05$ was considered significant.

Conclusion:

Irrespective of the clinical parameters, fascin expression is possibly involved in the etiology of OSCC; target therapy medicines can therefore be used in the future to treat this malignancy.

Key words:

•Fascin •Mouth Neoplasms •Carcinoma, Squamous Cell •Immunohistochemistry

Introduction

Oral squamous cell carcinoma (OSCC) is the most common form of oral cancer, accounting for approximately 91% of all oral malignancies.⁽¹⁾ The etiology of this carcinoma is multifactorial and both internal and external factors might affect its development. Despite using a combination of treatments including surgery, radiotherapy, and chemotherapy, the 5-year survival prospect is perceived in only approximately 40% of the patients and some die due to the secondary complications of cancer.⁽²⁾

Although surgery is still an appropriate treatment, it presents certain complications, such as chronic pain, dysphagia, dysphasia, and malformation.⁽³⁾ Radiotherapy and chemotherapy also have antitumor effects, but they damage the normal tissue. A better understanding of the molecular mechanisms and identification of the potential of oncogenes in OSCC could lead to the introduction of new adjunctive methods of treatment (molecular targeted therapy) for patients with oral cancer, which would result in fewer complications compared with other methods of treatment.⁽⁴⁾ Local tumor invasion and metastasis account for 90% of treatment failures. This aggressive behavior arises due to multiple phases that lead to the loss of cell adhesion. Fascin is a 55-kDa protein from the family of actin-bundling proteins that contributes a great share to the properties of cell junctions and their increased motility. In recent years, several studies have been conducted on this marker in normal and pathological tissues and several different roles have been attributed to it in the incidence of diseases such as neoplasms.^(5,6)

Given the role of fascin in cell adhesion, this protein may be used as a target for the treatment of OSCC and also as a marker for identifying aggressive malignant cell behaviors. As only a few studies have examined the role of fascin in OSCC⁽⁷⁻¹²⁾, the present study was therefore conducted to evaluate the expression levels of fascin in OSCC to gain more knowledge about fascin and OSCC and to also pave way for predicting tumor behavior and for finding a suitable treatment. Furthermore, given that, in many cases, non-smoking young individuals are diagnosed with tongue carcinoma, the present study as-

essed the relationship between this marker and age, gender, and tumor location.

Materials and Methods

The present study was retrospective and cross-sectional in design. Archived samples at the pathology laboratory of Taleghani Hospital and a private laboratory were examined and samples with an OSCC diagnosis were selected. Clinical and demographic data such as age, gender, and tumor location were extracted from the patients' records. Cases with sufficient data on the surveyed variables as well as the corresponding paraffin blocks with complete fixation and adequate tissue and with microscopic features of squamous cell carcinoma were finally selected.

Immunohistochemical (IHC) staining of paraffin blocks

The streptavidin-biotin method was used for staining. All samples were first fixed in 10% buffered formalin and then embedded in paraffin. Sections were prepared with a diameter of 4 mm and then deparaffinized and dehumidified by xylene and alcohol and washed with phosphate-buffered saline (PBS) and then placed in DAKO cytomation (PH = 9) in a microwave for 20 min for fixing the antigens. Internal oxidation was inhibited by addition of 3% hydrogen peroxidase. The slides were then incubated with monoclonal antibody (Dako, Denmark, clone55k-2, Code M3567) for 30 min according to the manufacturer's recommendations for examining fascin expression. After washing the slides with PBS for 5 min, they were immersed in Zymed streptavidin and incubated for 10 min. In the next step, the slides were exposed to 3,3'-Diaminobenzidine (DAB) hydrochloride as a chromogenic reagent, which produced a brown reaction product. The samples were then counterstained by hematoxylin and a coverslip was placed on them after dewatering.

A sample of Hodgkin's lymphoma was used as the positive control and the negative control was examined after the elimination of the primary antibody. Vascular endothelium was also taken as an internal positive control.

Method of interpreting the slides

Staining was assumed positive when the cytoplasm of the tumor cells was visibly stained. Fascin expression was determined based on the following items:

1. Percentage score (PS): According to the study conducted by Lee et al. ⁽¹⁰⁾, the number of stained cells was determined based on the DAB staining under an optical microscope, which were then divided into four groups. Score 1: less than 10% stained; score 2: 11-50% stained; score 3: 51-80% stained, and score 4: more than 81% stained.
2. Intensity score (IS): Score 0: no staining; score 1 (poor): staining is visible but with some difficulty; score 2 (medium): pale brown (oak); and score 3 (extreme): dark brown. To calculate the final score, PS was added to IS (0-7).

Results

The present study was conducted on OSCC samples of 25 patients with a mean age of 57.42 years (range: 27–90 years), of which 18 patients (72%) were males with a mean age of 59.41 years and 7 (28%) were females with a mean age of 52.57 years. The OSCC samples were mostly collected from the gingiva (10 cases or 40%) and the tongue (8 cases or 32%). In addition, four samples (16%) were collected from the buccal mucosa, two (8%) from the palate, and one (4%) from the lip. Fascin expression was analyzed in the OSCC samples using IHC staining. Fascin staining was cytoplasmic and fascin expression was confirmed in all the samples examined with a high score. All the samples obtained score 3 for their percentage score. For the intensity score, 24 samples obtained score 3 and 1 sample obtained score 2 (Figures 1 and 2).

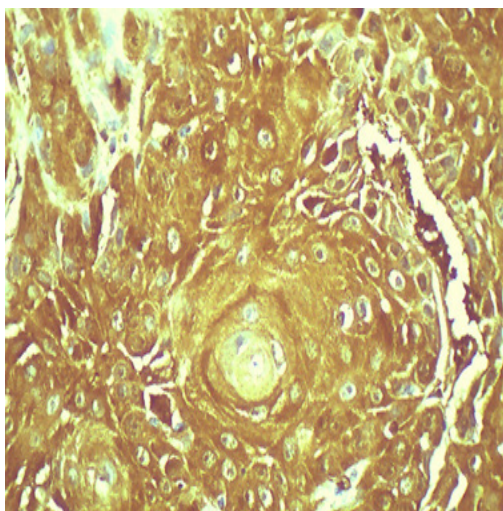


Figure 1. Cytoplasmic fascin expression in OSCC in malignant squamous cells with score 6 ($\times 400$)

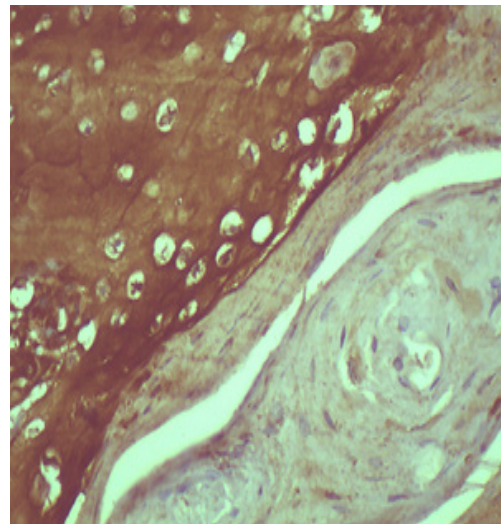


Figure 2. Cytoplasmic and membrane fascin expression in OSCC in the keratin pearl island with score 7 ($\times 400$)

The assumption in this study was that independent variables, particularly tumor location, were capable of affecting fascin expression. Given that all the samples had high scores in terms of their fascin expression levels (score 7 and, in one case, score 6), it was observed that fascin expression was not related to the patients' age and gender and tumor location. As the biopsy samples were mostly incisional, with few excisional cases, grading them was not possible. However, the tissues surveyed were primarily differentiated and the majority contained keratin pearls, and no poorly differentiated states were observed under the microscope. Malignant squamous cell islands were fascin-positive with or without the presence of keratin pearls.

Table 1. Fascin expression scores in OSCC by patients' demographic characteristics

		No of Samples	Percentage Score	Intensity Score	Total
Age (years)	<40	4	4	3	7
	41–55	12	4	3	7
	41–55	1	4	2	6
	56–70	4	4	3	7
	>70	3	4	3	7
Location	Gingiva	9	4	3	7
	Gingiva	1	4	2	7
	Tongue	8	4	3	7
	Palate	2	4	3	7
	Buccal Mucosa	4	4	3	7
	Lip	1	4	3	7
Gender	Male	17	4	3	7
	Male	1	4	2	6
	Female	7	4	3	7

Discussion

The present study showed overexpression of fascin in OSCC. Fascin expression level was not found to have a significant relationship with the patients' age and gender and tumor location. These results are consistent with the results of many other studies conducted on fascin expression and its relationship with gender, age, and tumor location.^(7, 9, 10, 11,12)

Similarly, Chen et al.⁽⁹⁾ did not find fascin expression intensity to have a relationship with age, gender, and tumor location and fascin expression percentage to have a relationship with the patients' age and gender. Although the majority of buccal mucosa samples expressed less than 55% fascin, the tongue samples of OSCC mostly expressed more than 55% fascin, which was statistically significant. Lee et al.⁽¹⁰⁾ also did not find fascin expression intensity to have a relationship with the patients' age and gender. Similar to the present study, they also reported that this protein was expressed in 91.3% of the samples. In the present study, the majority of samples were well differentiated under the microscope and contained keratin pearls (although their microscopic grade could not be determined). All the islands, with or without keratin pearls, overexpressed fascin. Consistent with our findings, Shimamura et al.⁽¹¹⁾ noticed fascin expression in epithelial dysplasia, carcinoma in situ, and also in OSCC, unlike in benign tumors such as papilloma. Therefore, it is quite natural for all of our samples to also overexpress this marker. It was suggested that fascin could be a useful tool for the accurate diagnosis of dysplasia and carcinoma in situ.⁽¹¹⁾ Fascin might therefore be involved in the early stages of carcinogenesis.

In contrast to the results obtained in our study on fascin expression, Alam et al.⁽⁷⁾ did not detect this protein in 25.19% of the cases and found that it had a poor expression in 41.98% of the samples and was overexpressed only in 32.28% of the cases.⁽¹³⁾ They also did not find fascin expression in the well-differentiated keratin-pearl-containing cases of OSCC. Moreover, unlike Chen and Alam^(7,9), other researchers^(10,12) did not find a relationship between grade, microscopic stage, and fascin expression; however, they found that a relationship was established when lymph nodes were involved. The possible

reasons for the disparity of results might be technical errors and the different steps of performing IHC staining, visual counting, using the computer, and the sample size examined. As in previous studies^(9,11), in the OSCC samples examined in the present study, fascin was primarily cytoplasmic-stained; however, due to its overexpression, the cell membrane was also stained in some cases. Nevertheless, Alam et al. also showed fascin expression in cell membranes in addition to that in the cytoplasm.⁽⁷⁾ Previous studies showed that fascin is either not expressed in normal oral epithelium or is expressed very poorly.⁽¹¹⁾ An interesting point, however, was that in the study conducted by Papaspyrou et al., 7 cases out of the 19 surveyed cases of normal epithelium showed score 2.⁽¹²⁾

The justification for this finding might be that the epithelia might have been derived from the vicinity of the tumor and might have therefore had the same environmental and pathological conditions, thus overexpressing the marker. The epithelia might be normal in macroscopic terms and under an optical microscope and might have experienced structural changes at the molecular level, and our slides also showed epithelia in some cases. However, the epithelium was not the subject for examination as it was in the vicinity of the tumor and hence will not be considered environmentally natural. Alam et al.⁽⁷⁾ found no relationship between fascin expression and invasion around the nerves. They also stated that fascin overexpression was observed in 17% of the N0 cases, and these patients should therefore be followed up to determine in the future whether fascin can act as a prognostic factor of occult metastasis or not. Papaspyrou et al.⁽¹²⁾ also concluded that fascin can be used to predict regional lymph node metastasis, and, in contrast to several studies^(7, 8,10), fascin expression was not associated with the reduced survival in their study. To better explain the role of this protein, several studies have investigated its function, including a study conducted by Chen⁽⁸⁾, who examined the function of fascin from the WNT signaling pathway through the stabilization of β -catenin mutation or the inactivation of APC gene and suggested that it increases the expression of this protein in cancer cells. In addition, Lee et al.⁽¹⁰⁾ stated that fascin expression is associated with the loss or reduction of E-cadherin, which is a

significant component of tumor cell invasion, and leads to the loss of cell–cell contact. Alam et al. ⁽⁷⁾ stated that fascin can disrupt the cell–cell contact and is involved in the formation and progression of primary OSCC tumor. Furthermore, fascin increases MMPs ^(2,9), which are proteolytic enzymes that digest the basement membrane content and facilitate metastasis.

They also found a strong relationship between fascin expression and lymph node involvement, confirming that the marker might facilitate the movement of tumor cells from the primary location to the lymph nodes. In the present study, the IHC staining method was used to examine fascin expression. Other methods can also be used to confirm the IHC staining results; for instance, the RT-PCR for analyzing fascin expression and the Western Blot for assessing fascin levels.⁽¹⁰⁾ However, further tests could not be conducted in the present study due to their high costs and the use of fixed samples. Alam et al.⁽⁷⁾

found actin components such as microspikes to be thicker and longer and showed the formation of more filopodia and lamellipodia, demonstrating a visibly increased cell motility in OSCC cell culture. Similarly, in another study on two OSCC cell lines, Chen et al.⁽⁸⁾ also concluded that fascin expression might have an essential role in the regulation and development of OSCC

that acts through epithelial-mesenchymal transition (EMT) and changes in E-cadherin and β -catenin. Chen et al. ⁽¹³⁾

tested migrastatin on breast cancer cells and found that this drug prevents cell migration, invasion, and metastasis by blocking fascin activity. The above-reviewed studies investigated the relationship between fascin expression levels and the clinical and histological conditions of OSCC and showed that increased fascin expression is associated with more invasive malignant cells and poorer prognosis. In the present study, all the samples showed the same score of fascin expression. i.e., ^(6,7) Data on the stage of the disease and patients' survival rates were not examined due to the incomplete pathological records. As a result, the effect of fascin expression levels and clinicopathological factors could not be investigated in this study.

Conclusion

Given the limitations of the present study, the results showed that fascin is overexpressed in OSCC samples, but its level is not associated with gender, age, and tumor location. Regardless of the clinical parameters, fascin expression is possibly involved in the etiology of OSCC, and target therapy medicines can therefore be used in the future for treating this malignancy.

References

1. Silverberg E, Boring CC, Squires TS. Cancer statistics, 1990. *CA Cancer J Clin.* 1990;40: 9-26.
2. Day G, Blot WJ. Second primary tumors in patients with oral cancer. *Cancer.* 1992 1;70:14-9.
3. Telfer MR, Shepherd JP. Psychological distress in patients attending an oncology clinic after definitive treatment for maxillofacial malignant neoplasia. *Int J Oral Maxillofac Surg.* 1993;22:347-9.
4. Le Tourneau C, Siu LL. Molecular-targeted therapies in the treatment of squamous cell carcinomas of the head and neck. *Curr Opin Oncol.* 2008;20:256-63.
5. Alaeddini M, Fouladdel S, Etemad-Moghadam S, Azizi E. Expression of Fascin and mRNA in the KB carcinoma cell line following treatment with doxorubicin. *J Cancer Res Ther.* 2011;7:427-32.
6. Tong GX, Yee H, Chiriboga L, Hernandez O, Waisman J. Fascin-1 expression in papillary and invasive urothelial carcinomas of the urinary bladder. *Hum Pathol.* 2005;36:741-6.
7. Alam H, Bhate AV, Gangadaran P, Sawant SS, Salot S, Sehgal L et al. Fascin overexpression promotes neoplastic progression in OSCC. *BMC Cancer* 2012 20: 12-32.
8. Chen SF, Lin CY, Chang YC, Li JW, Fu E, Chang FN, et al. Effects of small interfering RNAs targeting Fascin on gene expression in oral cancer cells. *J Oral Pathol Med.* 2009;38:722-30.
9. Chen SF, Yang SF, Li JW, Nieh PC, Lin SY, Fu E, et al. Expression of fascin in oral and oropharyngeal squamous cell carcinomas has prognostic significance - a tissue microarray study of 129 cases. *Histopathology.* 2007;51:173-83.
10. Lee TK, Poon RT, Man K, Guan XY, Ma S, Liu XB, et al. Fascin over-expression is associated with aggressiveness of OSCC. *Cancer Lett.* 2007 8;254:308-15.
11. Shimamura Y, Abe T, Nakahira M, Yoda T, Murata S, Sugasawa M. Immunohistochemical analysis of oral dysplasia: diagnostic assessment by fascin and podoplanin expression. *Acta Histochem Cytochem.* 2011 28;44:239-45.
12. Pappaspyrou K, Brochhausen C, Schmidtman I, Fruth K, Gouveris H, Kirckpatrick J et al. Fascin upregulation in primary head and neck squamous cell carcinoma is associated with lymphatic metastasis. *Oncol Lett.* 2014;7:2041-46.
13. Chen L, Yang S, Jakoncic J, Zhang JJ, Huang XY. Migrastatin analogues target fascin to block tumor metastasis. *Nature.* 2010 15;464:1062-6.