

Pneumatized Articular Tubercle and Pneumatized Roof of Glenoid Fossa on Cone Beam Computed Tomography: Prevalence and Characteristics in Selected Iranian Population

Original Article

Farzaneh Mosavat ¹, Ahura Ahmadi ²

¹Assistant Professor, Department of Oral and Maxillofacial Radiology, Faculty of Dentistry Tehran University of Medical Sciences, Tehran, Iran

²Assistant Professor, Shahid Beheshti University of Medical Sciences, Faculty of Medical Education, Tehran, Iran.

Received: Aug 2, 2015

Accepted: Oct 14, 2015

Corresponding Author:

Farzaneh Mosavat

Address:

Department of Oral and Maxillofacial Radiology, Faculty of Dentistry, Tehran University of Medical Sciences (TUMS), North Karegar Street, Tehran, Iran.

Telephone: +98-21-88351154

Email: F-mosavat@sina.tums.ac.ir

Abstract

Introduction:

Mastoid pneumatization is often complete by the age of 5-years and may involve the temporomandibular joint (TMJ) region, including the pneumatized articular tubercle (PAT) and pneumatized roof of the glenoid fossa (PRGF). To prevent surgical complications, the diagnosis of these air cells is important. The aim of this study was to determine the prevalence and characteristics of PAT and PRGF in the Iranian population.

Materials and methods:

In this cross-sectional study, convenience sampling was used to select participants. CBCT radiographs of 239 patients were evaluated retrospectively. Prevalence, location, age, and gender of patients with PAT and PRGF were determined. SPSS 18.0 was used for statistical analysis.

Results:

Of the 239 patients, 51 (21.3%) presented with PAT and 14 (5.9%) with PRGF. The mean age of the PAT patients was 47.92 ± 14.39 years. Unilateral PAT and PRGF were found in 35 (68.6%) and 8 (57.1%) patients, respectively. PAT prevalence was 51% in females and 49% in males.

Conclusion:

Surgeons planning TMJ intervention should evaluate radiographic imaging preoperatively to prevent intraoperative complications.

Key words: •Cone-Beam Computed Tomography •Glenoid Cavity Zygoma.

Introduction

Pneumatization is the development of air cell cavities, which are commonly detected in the skull. In addition, in the mastoid process, accessory air cells may be able to be located in the adjacent bone.⁽¹⁻³⁾ When these exist in the zygomatic process of the temporal bone, they are known as the pneumatized articular tubercle (PAT) and the pneumatized roof of the glenoid fossa (PRGF).^(4, 5) This asymptomatic radiolucency in the zygomatic process is similar to mastoid air cells.⁽⁶⁾ PAT is also called Zygomatic Air Cell Defects (ZACDs).⁽⁷⁾

The ZACD can be classified on the basis of their panoramic radiographic features as follows: unilocular and multilocular. A unilocular ZACD appears as a single radiolucent oval defect with well-defined borders; the multilocular type appears as numerous radiolucent small cavities, which look like mastoid air cells.^(5, 7)

In previous studies, panoramic radiography has typically been used to evaluate these defects. Owing to the anatomical complexity of the temporomandibular joint (TMJ), this technique is inadequate for assessing this region. Cone Beam Computed Tomography (CBCT) has recently been used as an alternative modality with higher accuracy for maxillofacial diagnostic purposes, such as the evaluation of cases with PAT and PRGF. Furthermore, the medial portion of the articular eminence could only be thoroughly assessed on CT or CBCT.^(2, 4, 8-12)

The recognition of these air cells is necessary from a surgical point of view. Penetration through this anatomic finding during surgical procedures may have disastrous outcomes.⁽¹³⁾ The aim of this study is to evaluate the prevalence and characteristics of PAT and PRGF with CBCT imaging in the Iranian population.

Materials and Methods

In this cross-sectional study, convenience sampling was used to recruit participants. CBCT radiographs of 239 patients (the sample size was determined as 230, where Δ : 0.5, power: 0.90, and α : 0.05), referred to the oral and maxillofacial radiology department of the Tehran University of Medical Sciences for paranasal sinus assessment, orthognathic surgery, TMJ evaluation, maxillofacial trauma, and pathological lesion

assessment. This study was performed retrospectively during the period from 2012 to 2014. Patients with anatomical pathology or a history of maxillofacial fractures in the zygomatic arch were excluded from the study.

Patients had been scanned with CBCT (Alphard-3030, Asahi; Roentgen, Tokyo, Japan), at 80 kVp, 5 mA, at a voxel size of 0.2 mm and a cylindrical volume of reconstruction of up to a 20-cm diameter and 17-cm height scan volume. On axial view, the long axis of the condylar head was traced, and the reconstructed lateral and frontal cross-sectional imaging perpendicular and parallel, respectively, to the long axis of the condyle. A maxillofacial radiologist assessed the images in a room with low ambient lighting. Image contrast and brightness were adjusted to ensure optimal visualization. The presence of PAT and PRGF, their locations (unilateral or bilateral), their internal structure (unilocular or multilocular) were assessed on CBCT (see Figure 1 a and b).

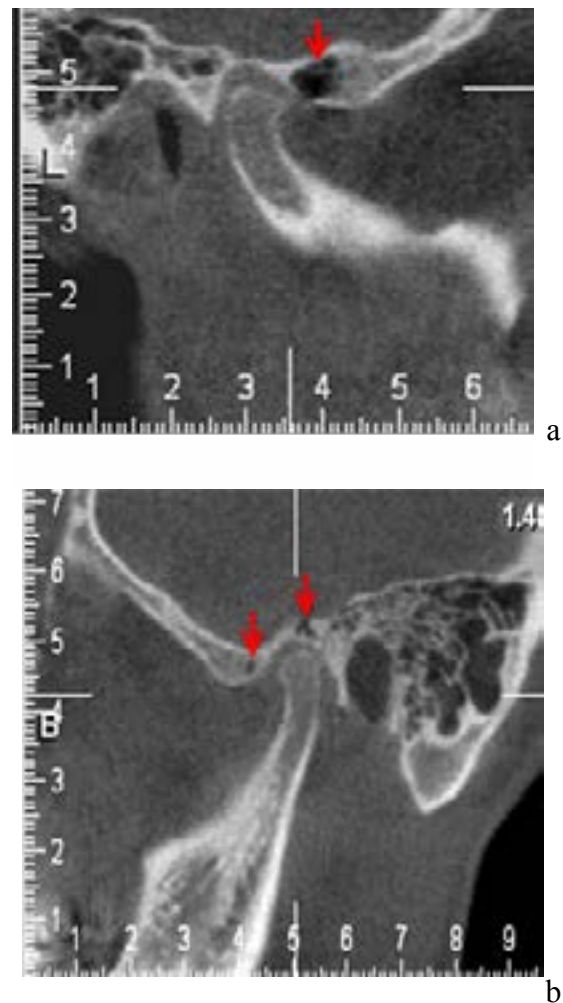


Figure 1: The presence of multilocular PAT (a) and multilocular PRGF and unilocular PAT (b):

SPSS 18.0 (Statistical Package for Social Sciences) for Windows® was used to analyse the data. The chi square test was used to compare differences among the variables. The level of significance was set at $p < 0.05$.

Results

The study sample consisted of 239 patients and 478 regions of interest (PAT and PRGF). 128 (53.6%) participants were females; 111 were males (Figures 2 and 3). The mean age of participants was 51.29 ± 13.38 years, with a range of 18–81 years. 51 (21.3%) participants presented with PAT; 14 (5.9%) with PRGF.

In individuals with PAT, 35 (68.6%) presented unilaterally, and 16 (31.4%) bilaterally. In individuals with PRGF, 8 (57.1%) presented with unilateral PAT, and 6 (42.9%) with bilateral PRGF.

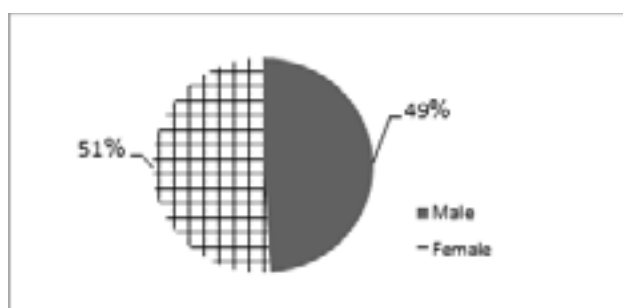


Figure 2: PAT according to gender

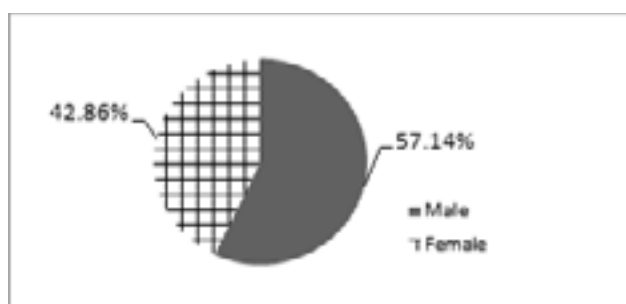


Figure 3: PRGF according to gender

Of the 51 patients with PAT, 26 (51%) were females and 25 (49%) were males. The mean age of PAT patients was 47.92 ± 14.39 years, with a range of 21–81 years. Of the PRGF patients, 6 (42.9%) were females and 8 (57.1%) were males. The mean age of PRGF patients was 45.07 ± 13.67 years, with a range of 25–66 years. For PAT and PRGF, no statistically significant differences were found with gender ($p = 0.59$). PAT and PRGF may be considered the mastoid

air cell extension equivalent of extensions of the paranasal sinuses.⁽¹²⁾ PAT and PRGF diagnosis is important because these defects may facilitate the spread of disease processes, including tumors, inflammation, and fractures along the joint, due to abnormal structures.⁽¹⁶⁾

Table 1: Prevalence, internal structure and location of PAT and PRGF on CBCT scans

		PAT Frequency	PRGF Frequency
		percentage	percentage
Total		51 (21.3%)	14 (5.9%)
Internal structure	Unilocular	24 (47.1%)	8 (57.1%)
	Multilocular	27 (52.9%)	6 (42.9%)
location	Unilateral	35 (68.6%)	10 (71.4%)
	Bilateral	16 (31.4%)	4 (28.6%)

Discussion

In a surgical procedure that manipulates the articular eminence, PAT may represent a complicating factor. Detection of these structures can help prevent undesirable complications.

Furthermore, awareness of the radiologic pattern of PAT and PRGF is useful in the differential diagnosis of pathological conditions involving this area.^(6, 12, 18)

The age range of patients with PAT and PRGF was 21 to 81 years (mean age: 47.92) and 25 to 66 years (mean age: 45.07), respectively, similar to that the ranges of 43.0–48.86 years reported in other studies.^(4,5,17,19) Pediatric patients were excluded from the present study, consistent with previous work.^(4,9,10,17) Pneumatization of the mastoid process is often complete by the age of five years, while pneumatization of zygomatic process begins at 9 years of age. The age at which air cell pneumatization of the articular eminence occurs remains unknown⁽²⁾, although the literature suggests that pneumatization of accessory air cells begins before puberty.⁽¹²⁾

Gender findings in this study were consistent with the literature in that the female-to-male ratio of PAT was 1.1:1.^(2, 12) In this study, there was no statistically significant difference between gender and the presence of PAT or PRGF, consistent with previous studies.^(4,20) In the present study, only 51 (21.3%) patients had PAT. The prevalence of PAT was assessed in the previous study mostly on panoramic radiographs, and re-

ported to be between 1 and 3.42%.^(9, 10, 12, 17) The reported prevalence of PAT on CBCT images varies in the literature, from 8%⁽¹²⁾ to 21.3%⁽⁴⁾ to 51.8%.⁽⁵⁾ Panoramic radiographs imply inherent problems, such as superimposition of adjacent structure, distortion, and low resolution. CBCT or CT is considered the modality of choice for the assessment of bony structures. Not only does CBCT not result in superimposition but it is also more diagnostically accurate compared to panoramic radiographs, for the assessment of air spaces in the skull base.⁽¹²⁾

In the current study, the prevalence of unilateral and bilateral PAT was 35 (68.6%) and 16 (31.4%), respectively. This is consistent with previous studies by Tyndall et al. and Kaugars et al.^(6,19)

Current literature on PAT revealed that the unilateral to bilateral ratio was 2.5:1⁽¹²⁾, similar to the present study, and that unilateral cases were more prevalent than bilateral cases (the observed ratio was approximately 2:1). In a previous study conducted with an Iranian sample, the ratio was 1.88:1 in panoramic imaging, which is close to the proportion reported in our study.⁽²⁾ In another study, the prevalence of unilateral ZACD (74.5%) was reported far more frequently than bilateral cases (25.5%) (ratio: 2.92:1).⁽³⁾

The higher ratio might be due to a difference in the region of interest. The ZACD includes a wider anatomical region than does PAT, which was assessed in our study.

In terms of type of pneumatization, most studies reported an almost equal distribution of unilocular and multilocular types^(2, 9-11, 17, 21, 22), except Laderia et al.⁽⁴⁾ and Zamaninaser et al.⁽³⁾, who reported a higher prevalence of the multilocular type, consistent with our study.

This may be related to the use of CBCT and to the ability to display clear images of air cells in the TMJ area, allowing the inspection of finer details of the anatomical structure. In the present study, the prevalence of PRGF was 5.9%. Differing prevalence rates were reported by Laderia et al. (38.3%)⁽⁴⁾, Groell et al. (51%)⁽²³⁾ and İlğüy et al. (11.7%).⁽⁵⁾ This difference might be attributed to various factors, including sample size, type of sample, and composition of the populations.

Conclusion

In conclusion, due to the importance of temporal air cells, the prevalence of PAT and PRGF should be assessed in every population. Surgical intervention in the pneumatized temporal bone can be complicated. In patients with PAT, perforation may occur during firm and forceful dissection or retraction. The use of CBCT is necessary to determine the exact size and the relationship to adjacent PAT tissue.

Acknowledgments

The authors would like to acknowledge all the participants and colleagues who helped and supported us in this study.

References

1. Stoopler ET, Pinto A, Stanton DC, et al. Extensive pneumatization of the temporal bone and articular eminence: an incidental finding in a patient with facial pain. Case report and review of literature. *Quintessence Int* 2003 Mar;34(3):211-4.
2. Shokri A, Noruzi-Gangachin M, Baharvand M, Mortazavi H. Prevalence and characteristics of pneumatized articular tubercle: First large series in Iranian people. *Imaging Sci Dent* 2013 Dec;43(4):283-7.
3. Zamaninaser A, Rashidipoor R, Mosavat F, Ahmadi A. Prevalence of zygomatic air cell defect: Panoramic radiographic study of a selected Esfahanian population. *Dent Res J (Isfahan)*. 2012 Dec;9(Suppl 1):S63-8.
4. Ladeira DB, Barbosa GL, Nascimento MC, et al. Prevalence and characteristics of pneumatization of the temporal bone evaluated by cone beam computed tomography. *Int J Oral Maxillofac Surg* 2013 Jun;42(6):771-5.
5. İlğüy M, Dolekoglu S, Fisekcioglu E, et al. Evaluation of pneumatization in the articular eminence and roof of the glenoid fossa with cone-beam computed tomography. *Balkan Med J*. 2015 Jan;32(1):64-8.
6. Tyndall DA, Matteson SR. Radiographic appearance and population distribution of the pneumatized articular eminence of the temporal bone. *J Oral Maxillofac Surg* 1985 Jul;43(7):493-7.
7. Carter LC, Haller AD, Calamel AD, Pfaffenbach AC. Zygomatic air cell defect (ZACD). Prevalence and characteristics in a dental clinic outpatient population. *Dentomaxillofac Radiol* 1999 Mar;28(2):116-22.
8. Hasnaini M, Ng SY. Extensive temporal bone pneumatization: incidental finding in a patient with TMJ dysfunction. *Dent Update* 2000 May;27(4):187-9.
9. Orhan K DC, Cebeci I, Paksoy C. Prevalence and variations of pneumatized articular eminence: a study from Turkey. *Oral Surg Oral Pathol Oral Radiol Endod* 2005;99:349-54.

10. Yavuz MS AM, Güngör H, Büyükkurt MC. Prevalence of the pneumatized articular eminence in the temporal bone. *J Craniomaxillofac Surg* 2009;37:137-9.
11. Barbosa GL NM, Ladeira DB, Bomtorim VV, da Cruz AD, Almeida SM. Accuracy of digital panoramic radiography in the diagnosis of temporal bone pneumatization: A study in vivo using cone-beam-computed tomography. *J Craniomaxillofac Surg* 2014;42:477-81.
12. Miloglu O, Yilmaz AB, Yildirim E, Akgul HM. Pneumatization of the articular eminence on cone beam computed tomography: prevalence, characteristics and a review of the literature. *Dentomaxillofac Radiol* 2011 Feb;40(2):110-4.
13. Patil K MV, Malleshi SN, Srikanth HS. Prevalence of zygomatic air cell defect in adults-A retrospective panoramic radiographic analysis. *Eur J Radiol* 2011;81:957-9.
14. Görür K OC, Talas D. The computed tomographical and tympanometrical evaluation of mastoid pneumatization and attic blockage in patients with chronic otitis media with effusion. *Int J Pediatr Otorhinolaryngol* 2006;70:481-5.
15. Pata YS AY, Unal M, Duce MN, et al. The relationship between presbycusis and mastoid pneumatization. *Yonsei Med J*. 2004;45:68-72.
16. Betz BW WM. Air in the temporomandibular joint fossa: CT sign of temporal bone fracture. *Radiology* 1991;180:463-6.
17. Hofmann T, Friedrich RE, Wedl JS, Schmelzle R. [Pneumatization of the zygomatic arch on pantomography]. *Mund Kiefer Gesichtschir*. 2001 May;5(3):173-9. German.
18. Kulikowski BM SS, Kraut RA. Surgical management of a pneumatized articular eminence of the temporal bone. *J Oral Maxillofac Surg* 1982;40:311-3.
19. Kaugars GE ML, Laskin DM. Pneumatization of the articular eminence of the temporal bone: prevalence, development, and surgical treatment. *J Am Dent Assoc* 1986;113:55-7.
20. White SC PM. *Oral Radiology Principles and Interpretation*. 7th ed. USA: Mosby, Elsevier; 2014.
21. Orhan K DC, Orhan AI. Radiographic evaluation of pneumatized articular eminence in a group of Turkish children. *Dentomaxillofac Radiol* 2006;35:365-70.
22. Orhan K OU, Orhan AI, Ulker AE, et al. Investigation of pneumatized articular eminence in orthodontic malocclusions. *Orthod Craniofac Res* 2010;13:56-60.
23. Groell R FB. The pneumatic spaces of the temporal bone: relationship to the temporomandibular joint. *Dentomaxillofac Radiol* 1999;28:69-72