

Mandibular Second Premolar with Three Roots: A Case Report

Case Report

Leila Atash Biz Yeganeh¹

¹Assistant Professor of Endodontics, Department of Endodontics, Faculty of Dentistry, Guilan University of Medical Sciences, Rasht, Iran.

Received: Jun 22 , 2015

Accepted: Oct 10 , 2015

Corresponding Author:

Leila Atash Biz Yeganeh

Address: Department of Endodontics, Faculty of Dentistry, The End of Professor Samii Blv. Guilan University of Medical Sciences Complex, Rasht, Iran.

Telephone:+98-13-33486428

Email:yeganehdds@gmail.com

Fax:+98-13-33486717

Abstract

Human mandibular premolars have earned the reputation for having an extremely complex root and root canal morphology. The incidence of multiple roots and canals in mandibular second premolars is lower than those in mandibular first premolars. Mandibular second premolars with three root canals and separate foramina are very rare. In this case report, endodontic management of a three-rooted mandibular second premolar is discussed.

Key words:

●Mandible ●Bicuspid ●Root

Case Report

A 24-year-old male with a noncontributory medical history was referred by his general dental practitioner for the endodontic treatment of his mandibular left second premolar. Clinical examination revealed a carious lesion in the tooth. The tooth was highly sensitive to a cold test, but there was no tenderness on percussion. A diagnosis of symptomatic irreversible pulpitis was made. Radiographic interpretation revealed the presence of a complex root canal anatomy indicative of more than two root canals (Figure 1).

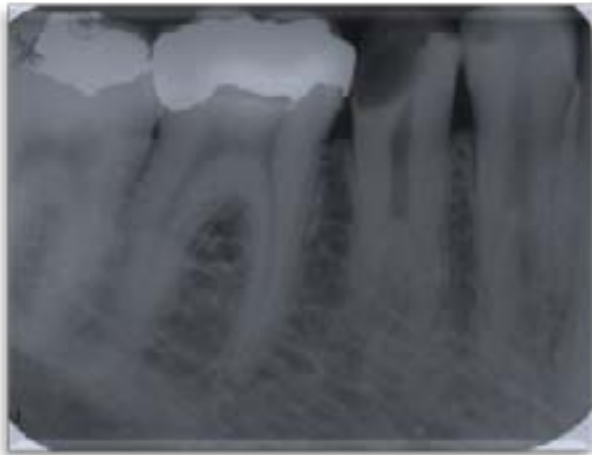

Figure 1: Preoperative radiograph

The tooth was anesthetized with 2% lidocaine containing 1:100,000 epinephrine (Daroupanksh, Tehran, Iran) and isolated with a rubber dam. The carious lesion was removed and access cavity was made to an ovoid outline. A large orifice was apparent up to the mid-length of the root. After enlarging the orifice with Gates-Glidden burs (Dentsply Maillefer, Ballaigues, Switzerland), two orifices (mesiobuccal and distobuccal) were evident. The canals were negotiated with size 10 K-files (Kerr, Karlsruhe, Germany). To provide access and visibility for searching extra root canals, the lingual wall of the access cavity was extended towards the lingual and the mesiodistal dimensions. Finally, using a precurved size 10 K-file (Kerr, Karlsruhe, Germany), a root canal was found in the mesiolingual part. Instruments were inserted into the canals according to the estimated working length, which was confirmed with an electronic apex locator (Root ZX; Morita, Irvine, CA, USA) and a periapical radiograph (Figure 2). The root canals were prepared using the RaCe rotary system (FKG Dentaire,

La chaux-de-Fonds, Switzerland) and RC Prep (Premier, Norristown, PA, USA) as a lubricant. The last file inserted in each root canal was file size 30, 0.04 taper.

For irrigation, an ultrasonic device was attached to a size 20 K-file and inserted into each canal, which was filled with sodium hypochlorite solution (2.5%). The canals were dried with paper points, and obturated with laterally condensed gutta-percha and AH 26 sealer (Dentsply Maillefer, Ballaigues, Switzerland). Finally, the tooth was restored with post-and-core and crown (Figure 3)

Twelve months later, the patient was symptom-free and a follow-up radiograph (Figure 4) revealed a continuous periodontal space with no signs of periapical abnormal radiographic changes.

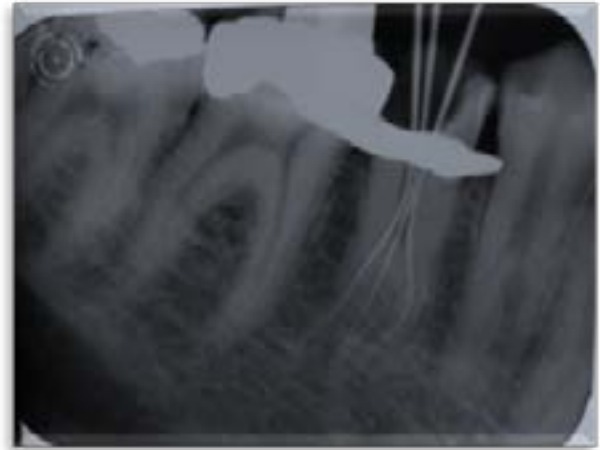


Figure 2: Working length radiograph, which shows three roots.

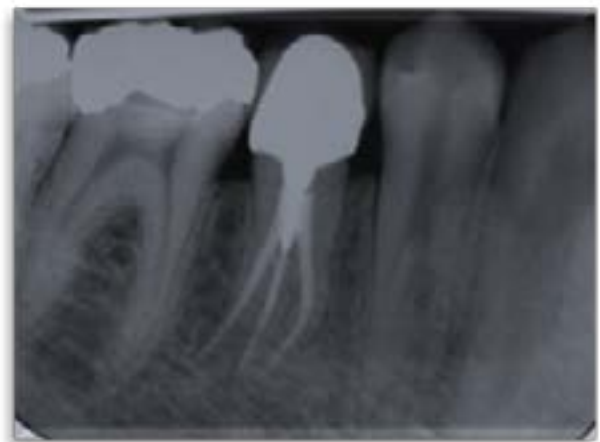


Figure 3: Root canal treatment and restoration.

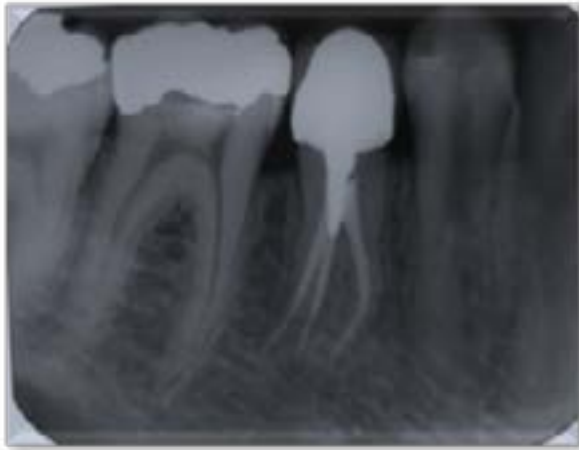


Figure 4: Twelve-month follow-up.

Discussion

Mandibular premolars may present the greatest difficulty for endodontic treatment and have the highest treatment failure rate.^(1,2) The reasons for a high failure rate include variations in root canal morphology and difficult access to irregularities.⁽³⁾ The canal morphology of the mandibular second premolar is similar to that of the first premolar; however, these variations are less often found in the second premolar.⁽⁴⁾

Mandibular second premolars present with a higher incidence of one root (99.6%) and one canal (91.0%) in comparison to mandibular first premolars.⁽³⁾ The incidence of two roots (0.3%) and three roots (0.1%) is extremely rare.⁽³⁾ The root and root canal morphology of the mandibular second premolar can be extremely complex and requires careful assessment.^(3,5,6)

Some of the root canal anatomic aberrations reported as cases in the literature include mandibular second premolars with three root canals,⁽⁷⁻¹³⁾ four root canals,⁽¹⁴⁻¹⁸⁾ four root canals,⁽¹⁹⁾ three separate roots with taurodontism,⁽²⁰⁾ and C-type morphology.⁽⁶⁾

The primary step in root canal treatment is to identify the internal morphology of the canal system. Generally, high-quality radiographs should be obtained at different horizontal angulations (15°–40°) to carefully evaluate the presence of extra root canals in the mandibular premolars.⁽²⁾ The presence of an additional canal should be suspected whenever an instrument demonstrates an eccentric direction or appears off center in the radiograph.⁽⁹⁾ Thorough tactile examination of the access cavity, and particularly the major canal, with the tip of a precurved

file is recommended to find additional root canals. In mandibular premolars with three canals, the cervical half of the root is generally wider than usual⁽⁵⁾ as observed in the present case. In addition, observation of more than one periodontal ligament spaces on one side of a root and the periodontal ligament space crossing over roots are both indicative of the presence of more than two roots.

The root canal system of premolars with three root canals is characterized by one large lingual canal and two smaller canals in the mesiobuccal and distobuccal roots.⁽³⁾ In this case report, as reported previously by Bhardwaj et al.,⁽²¹⁾ two root canals were located mesially, named mesiobuccal and mesiolingual and the third root was located in the distobuccal region.

The characteristic of mandibular premolars with three root canals is the presence of a triangle-shaped pulp chamber.⁽²²⁾ The triangular outline was similar to the pulp chamber observed in this case report, in which the distance from the mesiobuccal to the lingual orifices was the highest. This geometric configuration could be helpful for locating the distobuccal canal.

There is direct evidence to correlate certain anatomic variations in mandibular premolars to specific ethnic and geographic populations.⁽³⁾

A review revealed statistically significant intra-ethnic and interethnic correlations among Caucasian, Indian, Mongoloid, and Middle Eastern ethnicities in terms of the number of roots, root canals, and apical foramina found in mandibular bicuspsids.⁽³⁾ According to reported studies,^(1,23) females had a higher likelihood of having two or more roots or root canals in the mandibular first premolars, whereas men exhibited multiple canals in the mandibular second premolars much more frequently than females, as presented in this case report. However, differentiation between each variation has not been reported according to race and gender.

Conclusion

Although the incidence of mandibular second premolars with three separate roots is low, each case should be investigated carefully, both clinically and radiographically, to detect additional root canals.

References

- 1.Sert S, Bayirli GS. Evaluation of the root canal configurations of the mandibular and maxillary permanent teeth by gender in the Turkish population. *J Endod* 2004;30(6):391-8.
- 2.Albuquerque D, Kottoor J, Hammo M. Endodontic and clinical considerations in the management of variable anatomy in mandibular premolars: a literature review. *Biomed Res Int* 2014;2014:512574. doi: 10.1155/2014/512574. Epub 2014 May 8.
- 3.Kottoor J, Albuquerque D, Velmurugan N, Kuruvilla J. Root anatomy and root canal configuration of human permanent mandibular premolars: a systematic review. *Anat Res Int* 2013;2013:254250. doi: 10.1155/2013/254250. Epub 2013 Dec 22.
- 4.Cleghorn BM, Christie WH, Dong CC. The root and root canal morphology of the human mandibular second premolar: a literature review. *J Endod* 2007;33(9):1031-7.
- 5.Nallapati S. Three canal mandibular first and second premolars: a treatment approach. *J Endod* 2005;31(6):474-6.
- 6.Cleghorn BM, Christie WH, Dong CC. Anomalous mandibular premolars: a mandibular first premolar with three roots and a mandibular second premolar with a C-shaped canal system. *Int Endod J* 2008;41(11):1005-14.
- 7.Kararia N, Kararia V. Root canal treatment of a mandibular second premolar with atypical canal pattern. *J Conserv Dent* 2012;15(4):392-4.
- 8.Hariharavel VP, Kumar AA, Ganesh C, et al. Root canal treatment of mandibular second premolar with three separate roots and canals using spiral computed tomographic. *Case Rep Dent* 2014. doi: 10.1155/2014/816576.
- 9.Rödiger T, Hülsmann M. Diagnosis and root canal treatment of a mandibular second premolar with three root canals. *Int Endod J* 2003;36(12):912-9.
- 10.De Moor RJ, Calberson FL. Root canal treatment in a mandibular second premolar with three root canals. *J Endod* 2005;31(4):310-3.
- 11.Shokouhinejad N. Root canal re-treatment of a mandibular second premolar with three root canals: a case report. *Aust Endod J* 2009;35(3):180-2.
- 12.Lotfi M, Vosoughhosseini S, Zand V, et al. A mandibular second premolar with three canals and atypical orifices. *J Oral Sci* 2008;50(3):363-6.
- 13.Soares LR, Arruda M, de Arruda MP, et al. Diagnosis and root canal treatment in a mandibular premolar with three canals *Braz Dent J.* 2009;20(5):424-7.
- 14.Farmakis ET. Four-rooted mandibular second premolar. *Aust Endod J* 2008;34(3):126-8.
- 15.Al-Fouzan KS. The microscopic diagnosis and treatment of a mandibular second premolar with four canals. *Int Endod J* 2001;34(5):406-10.
- 16.Rhodes JS. A case of unusual anatomy: a mandibular second premolar with four canals. *Int Endod J* 2001;34(8):645-8.
- 17.Tzanetakos GN, Lagoudakos TA, Kontakiotis EG. Endodontic treatment of a mandibular second premolar with four canals using operating microscope. *J Endod.* 2007;33(3):318-21.
- 18.Sachdeva GS, Ballal S, Gopikrishna V, Kandaswamy D. Endodontic management of a mandibular second premolar with four roots and four root canals with the aid of spiral computed tomography: a case report. *J Endod* 2008;34(1):104-7.
- 19.Macri E, Zmener O. Five canals in a mandibular second premolar. *J Endod* 2000; 26(5):304-5.
- 20.Mokhtari H, Niknami M, Zand V. Managing a mandibular second premolar with three-canal and taurodontism: a case report. *Iran Endod J* 2013;8(1):25-8.
- 21.Bhardwaj A, Kottoor J, Albuquerque DV, Velmurugan N. Morphologic variations in mandibular premolars: a report of three cases. *J Contemp Dent Pract* 2014;15(5):646-50.
- 22.Parekh V, Shah N, Joshi H. Root canal morphology and variations of mandibular premolars by clearing technique: an in vitro study. *J Contemp Dent Pract* 2011;12(4):318-21.
- 23.Iyer VH, Indira R, Ramchandran S, Srinivasan MR. Anatomical variations of mandibular premolars in Chennai population. *Indian J Dent Res* 2006;17(1):7-10