

Mandibular First Molar with Five Canals: A Report of Three Cases

Case Report

Elnaz Mosavi Khoonsari¹, Maryam ghamari²

¹Assistant Professor, Department of Endodontics, Faculty of Dentistry, Guilan University of Medical Sciences, Rasht, Iran.

²Assistant Professor, Department of Endodontics, Faculty of Dentistry, Qazvin University of Medical Sciences, Ghazvin, Iran.

Received: Sep 11, 2015

Accepted: Dec 6, 2015

Corresponding Author:

Elnaz Mosavi Khoonsari

Address: Department of Endodontics, Faculty of Dentistry, The End of Professor Samii Blv. Guilan University of Medical Sciences Complex, Rasht, Iran.

Telephone:+98-13-33486428

Email: elnaz32@gmail.com

Fax: +98-13-33486423

Abstract

Introduction:

The main objective of endodontic therapy is the thorough mechanical and chemical cleansing of the entire root canal system and its complete obturation with an inert filling material. Failure to find and fill a canal contributes toward the failure of endodontic therapy. The root canal anatomy of mandibular first molars is complex. Studies of the morphologic structure of root canal systems have demonstrated the complexity, numbers, and distributions of canals in mandibular first molars. Approximately 2.75% of mandibular first molars have been found in five canals. Although the presence of middle mesial canals in mandibular molars is rare, but finding them is essential for a successful root canal treatment. In this study, we present three mandibular first molars with three canals in the mesial root.

Key words:

•Molar •Root Canal Therapy •Morphology

Case Report

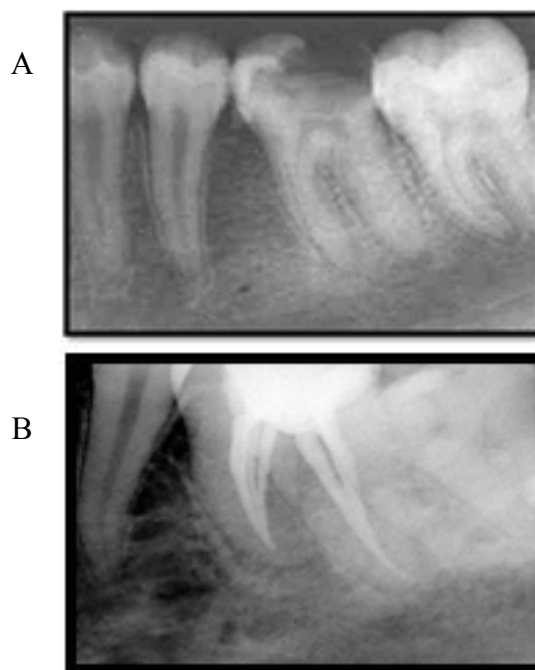Case 1

A 45-year-old female, whose general anamnesis contained no abnormal data, was sent to my office for endodontic treatment of the left mandibular first molar (Figure 1A). The symptoms were mild but continuous pain caused by sensitivity to cold (Endo Ice, Hygienic Corp., Akron, OH), electric pulp tester (EPT, Analytic Technology), and tender upon percussion. No periodontal pockets or sinus tract were detected and tooth mobility was within normal limits. Following the administration of lidocaine 2% with 1:80000 epinephrine (Daroupakhsh, Tehran, Iran), the tooth was isolated with a rubber dam. An extensive distocclusal cavity was found and irreversible pulpitis was diagnosed. Four independent canals were located. These were catheterized. During treatment, a depression was felt in the pulp chamber floor toward the center of the mesial root canal entrances. There is a mesiolingual canal and a middle mesial canal (MM) that converges with the mesiolingual at the middle third to terminate together at the apex. The distal root shows two canals with two independent foramina that are connected at the cervical third and have a common entrance in the pulp chamber floor. The cleaning and shaping of the canals was performed using a ProTaper rotary system (Dentsply, Maillefer, Switzerland), except for the MM canal that was cleaned with the Mtwo rotary system (VDW. GmbH, Germany). Copious irrigation with sodium hypochlorite 2.5% was maintained throughout the instrumentation procedure. The canals were obturated with a cold lateral condensation technique using gutta-percha (Gapadent, Hamburg, Germany) and AH plus sealer (Dentsply, Maillefer, Switzerland) (Figure 1B). The tooth was temporarily sealed using Cavit, and the patient was referred for permanent restoration.

Case 2

A 26-year-old male, whose medical history showed no abnormal data, was sent to my office for root canal therapy. Extensive mesioocclusal amalgam filling was observed in his right mandibular first molar. Vitality tests were done for this tooth. The diagnosis was irreversible pulpitis and acute apical periodontitis. Initially, three canals were located and catheterized. Once the

mesiobuccal canal was dried with paper points, a bloodstain appeared on the apical third of the paper points which made us suspect another canal. The area between the openings of both mesial canals in the pulp chamber floor was explored and a third canal located. Preparation of canals was performed exactly as in Case 1. A Radiograph with distal angle was performed after obturation (Figure 2). It showed a mesiolingual canal, independent in its path toward the apex, a mesiobuccal canal, and a third intermediate canal (MM canal) converging with the mesiobuccal in the apical third and terminating at the apical foramen. The distal root had two canals (Figure 2).



(A: Primary radiography, B: Initial working length, C: Final radiography)

Figure 1. Left mandibular first molar with five canals

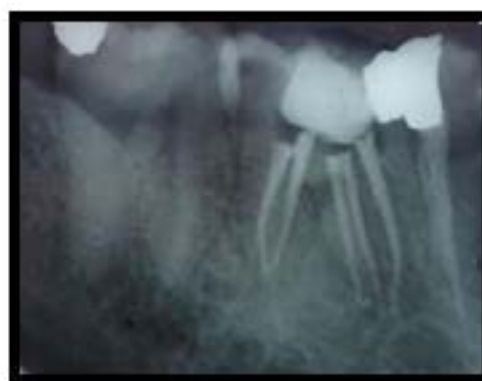

Figure 2. Right mandibular first molar with five canals.

Case3

A 37-year-old male presented at the emergency dental clinic with pain associated with the mandibular left first molar. Periodontal probing depths were 4 to 5 mm, and a significant amount of gingival inflammation was observed. The control teeth responded to cold within normal limits (Endo Ice, Hygienic Corp., Akron, OH) and percussion. The mandibular left first molar was hypersensitive to percussion and cold test. A diagnosis of irreversible pulpitis with acute apical periodontitis was made for the mandibular left first molar. No apparent radiographic anomalies were identified preoperatively. Regional anesthesia was administered and the tooth isolated with a rubber dam. All caries was removed and access to the pulp chamber was completed. Three canals were initially identified and a working length radiograph was taken with 15 K-files (Dentsply, Maillefer, Switzerland). The pulpal floor was further examined with an endodontic explorer Star DG-16 (Hu-Friedy, US), revealing a second canal in the distal root and a third orifice in the groove between the two primary mesial canals (mesiobuccal and mesiolingual), closer to the buccal.

All canals were instrumented to a size 20 K-file and other steps of cleaning and shaping of root canals were the same as in Case1 and 2. Upon verification of master cone length, the canals were obturated by lateral condensation with AH 26 sealer (Dentsply, Maillefer, Switzerland) sealer and gutta-percha (Gapadent, Hamburg, Germany). Final obturation radiograph was taken with distal angulation (Figure 3). The mesiolingual and middle mesial canal communicating in the middle third and mesiobuccal canal was separate.

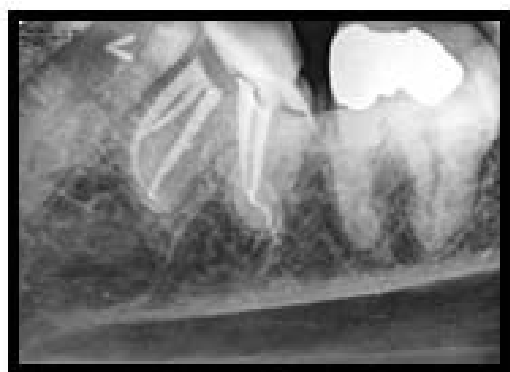


Figure 3. Left mandibular molar with five canals.

Discussion

Most first mandibular molars have at least three principal canals, extending from the orifice to the apical foramen. These canals are of varying sizes and diameter according to the age of the tooth and to the injuries it has sustained (for example, caries, and occlusal trauma). Two mesial canals and one or two distal canals are normally found.⁽¹⁾ To find the middle mesial or distal canals, however, requires more precise and complete removal of the dentin shelf, because the orifices of these canals are unclear.

Fabra Campos⁽¹⁾ has described the extra canal as an intermediate canal, but Bond et al.⁽²⁾ and Pomeranz et al.⁽³⁾ describe it as the middle mesial canal. This canal is located in the developmental groove between the mesiobuccal and mesiolingual root canal systems.⁽⁴⁾

Correct access to the pulp chamber, which should allow access to the orifices of the root canals and an optimal view of the chamber floor, is fundamental to endodontic therapy, enabling the identification of variations in the number and position of root canals.⁽⁵⁾

The presence of an unfilled canal may explain some of the endodontic failures associated with teeth, even though radiographically and clinically the canal system seems to be obturated.⁽⁶⁾

A systematic review study in mandibular first molars revealed that three canals were present in 61.3%, four in 35.7%, and five in approximately 1%.⁽⁷⁾

Fabra-Campos suggested four steps to easily locate these intermediate canals within the mesial root.

1. First the access cavity is made, and the pulp chamber is dried. A round bur is used to eliminate the dentin from the mesial wall.
2. A thin explorer is brought from the orifice of the mesiobuccal canal toward that of the mesiolingual, to search for any possible intermediate depression.
3. By using a thin file (#08 or 10) in an alternating 45-degree rotating motion, one can catheterize the third canal (the "intermediate canal").
4. Once the canal is located, a fine burs drill may be used to widen the canal entrance.⁽¹⁾

Reeh said "Looking at the pulpal "footprint" and other adjunctive techniques helps improve the likelihood of finding additional canals. The pul-

pal footprint is the lines and shadows on the floor of the pulp chamber that help guide us to areas where additional canals may be located.”⁽⁸⁾

Tactile sense can assist in locating where a canal bifurcates or when it may help to use the ultrasonic surgical handpiece to remove a small amount of tooth structure that may occlude a canal orifice.

Of course, adequate visibility is a prerequisite, which means good access and possibly removing restorations, crowns, and bridges.⁽⁸⁾ In addition, there are multiple concepts, armamentaria and instruments that are useful in finding these aberrant canals. These include the use of micro-openers, bubble test, champagne test, transillumination, looking for the rules of symmetry, red line test, white line test and perio-probing.⁽⁹⁾

According to the cases described here, the clinician needs to be aware of root canal anatomy and variation in the number of roots and canals in order to achieve successful root canal therapy.

Conclusion

An accurate knowledge of the morphology of the pulp chamber and root canals is essential before an endodontic procedure. The frequency with which root canals unite should be considered during enlargement and filling procedures. The dentist should also be familiar with the possible existence of bifurcated and double canals if root canal therapy should unexpectedly fail.

References

- 1.Fabra-Campos H. Unusual Root Anatomy of Mandibular First Molars. *J Endod* 1985; 11(12): 568-72.
- 2.Bond J, Hartwell G, Donnelly J, Portell F. Clinical management of middle mesial root canals in mandibular molars. *J Endodon* 1988;14: 312-14.
- 3.Pomeranz H, Eidelman D, GoLdberg M. Treatment considerations of the middle mesial canal of mandibular first and second molars. *J Endodon* 1981 ;7 :565- 8.
- 4.Hasan M, Umer F. Endodontic retreatment of a mandibular first molar with five root canal systems: an important clinical lesson. *BMJ Case Rep*; 2014. doi: 10.1136/bcr-2013-201402.
- 5.Ahmed HA, Abu-bakr NH, Yahia NA, Ibrahim YE. Root and canal morphology of permanent mandibular molars in a Sudanese population. *IEJ* 2007; 40: 766–771.
- 6.Vertucci FJ. Root canal anatomy of the human permanent teeth. *Oral surg* 1984; 58: 589-99.
- 7.de Pablo OV, Estevez R, Péix Sánchez M, et al. Root anatomy and canal configuration of the permanent mandibular first molar: a systematic review. *J Endod.* 2010; 36(12):1919-31.
- 8.Reeh ES. Seven Canals in a Lower First Molar. *Journal of endodontics* 1998; 24(7): 497
- 9.Kottoor J, Sudha R, Velmurugan N. Middle distal canal of the mandibular first molar: a case report and literature review. *IEJ* 2010; 43, 714–722.