

# Efficacy of Pseudocolor Tool of Digital System in the Detection of Proximal Caries

## Original Article

Seyedeh Tahereh Mohtavipour<sup>1</sup>, Alieh Sadat Javadzadeh Haghghat<sup>1</sup>, Seyedeh Saeideh Mohtavipour<sup>2</sup>, Zahra Dalili Kajan<sup>3</sup>, Fatemeh Shahsavari<sup>4</sup>, Habibeh Alimohammadi<sup>5</sup>

<sup>1</sup> Assistant Professor, Department of Maxillofacial Radiology, Guilan University of Medical Sciences, Rasht, Iran.

<sup>2</sup> Assistant Professor, Department of Pediatric Dentistry, Guilan University of Medical Sciences, Rasht, Iran.

<sup>3</sup> Professor, Department of Maxillofacial Radiology, Guilan University of Medical Sciences, Rasht, Iran.

<sup>4</sup> Assistant Professor, Department of Maxillofacial Pathology, Dental Branch, Islamic Azad University, Tehran, Iran.

<sup>5</sup> Dentist, Department of Maxillofacial Radiology, Guilan University of Medical Sciences, Rasht, Iran.

Received Sep 13, 2015  
Accepted: Dec 21, 2015

### **Corresponding Author:**

**Alieh Sadat Javadzadeh Haghghat**

### **Address:**

Guilan University of Medical Sciences, Rasht, Iran.

**Telephone:** +981333486428

**Email:** drjavadzadeh@yahoo.com

## **Abstract**

### **Introduction:**

Various intraoral digital radiographic systems are available as an alternative to film-based radiography. Recent rapid progress in the field of digital radiography offers the possibility of image processing and manipulation. Pseudocolor filter is one of the tools of digital systems. The aim of this study was to compare diagnostic accuracy of proximal caries in black and white and colorized images.

### **Materials and methods:**

In this in vitro study, forty extracted premolar were selected and mounted in acrylic blocks. The teeth were radiographed with complementary metal-oxide semiconductor (CMOS) digital sensor. Two observers evaluated the images with and without application of the pseudocolor tool. The teeth were sectioned for histological determination of the lesion. The diagnostic accuracy of each method was assessed by means of ROC analysis

### **Results:**

There were no significant differences between the black and white and colored mode of images ( $P = 0.973$ ). There were no significant differences between observers.

### **Conclusion:**

Color mode of digital images can be used for proximal caries detection.

### **Key words:**

•Dental Caries •Diagnosis •Digital Dental Radiography.

## Introduction

Radiography is useful for detecting carious lesions because the caries process causes demineralization of the enamel and dentin. Proximal caries are commonly found at the interface between the proximal surfaces of the tooth and free gingival margin. Since the proximal surfaces of posterior teeth are mostly broad, their minor demineralization is often difficult to detect in the radiograph. Digital image receptors may replace film for intraoral radiography. Various types of digital sensors are available. One of these detectors is the complementary metal-oxide semiconductor (CMOS).

Digital intraoral receptors require less radiation than film, thus reducing patient exposure. In addition, digital imaging allows enhancements, measurements, and corrections that are not available with film.<sup>(1)</sup>

Most digital systems on the market provide opportunities for color conversion of grayscale images, which is also called pseudocolor. Transforming the gray values of a digital image into various colors could theoretically enhance the detection of objects within the image.<sup>(1)</sup> Most studies on caries detection have compared digital and conventional radiography and suggested similar accuracy of both methods.<sup>(2-11)</sup> However, limited studies have evaluated the efficacy of software packages such as pseudocolor filters offered for digital systems.

This study aimed to investigate the efficacy of pseudocolor software with a CMOS sensor in the detection of proximal caries.

## Materials and Methods

In this in vitro study, Forty extracted human premolars were selected on the basis of varying caries depth. Premolar teeth extracted on orthodontic indications were used because sound surfaces and small caries between them were found. The teeth were evaluated clinically and radiographically for the presence of proximal caries. The roots of the teeth were embedded in plaster and arranged in groups of four. In each block, we used two selected premolars; one canine and one molar tooth for making proximal contact surface. However, only premolars were considered in this study. An apparatus was fabricated to allow for a constant spatial relationship

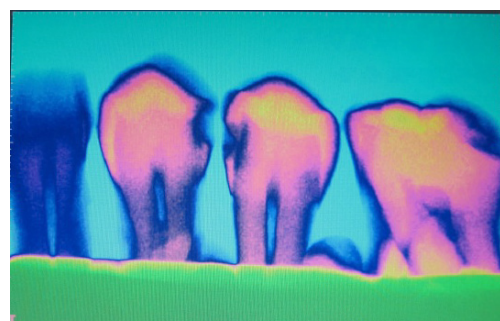
among the X-ray source, teeth, and receptor. The angulation and position of central ray was fixed bringing the sensor against a ring of film holder (RWT, Regular, Germany) by the end of the (PID) position indicating device; (Figure 1).



**Figure 1.** Prefabricated tool for imaging of the samples

The distance from the X-ray source to sensor was 40 cm. A 0.5 cm thick glass plate was used for the simulation of X-ray absorbing and scattering properties of soft tissue.<sup>(12)</sup> The teeth were imaged using the CMOS (USA-Schick) by a planmeca unit (Planmeca, Helsinki, Finland) operating at 70 kvp and 8 mA. The optimal exposure time was established during a pilot study to the 0.2s. Two oral and maxillofacial radiologists with the same experience independently evaluated all the images.

Images were displayed on a 17 inch monitor (Ben Q, Taipei, Taiwan) with a resolution of 1024 × 768 and a grayscale of 0–255. The evaluations were done once on the black and white images and then by using the pseudocolor software (Figure 2).



**Figure 2.** grayscale and colored images

Observers viewed the images and recorded their diagnosis using the ordinal caries depth rating scale: 0, no caries; 1, caries restricted to enamel;

2, caries reaching to DEJ; and 3, caries extending into the dentin. After imaging, the teeth were sectioned with a diamond disk. An oral pathologist examined the tooth sections using a stereomicroscope (Olympus SZ X12, Tokyo, Japan) based on the rating scales and the results were recorded as gold standard for the presence of caries (Figure 3). Receiver operating characteristic (ROC) analysis was used to assess the diagnostic accuracy of the imaging modalities. The areas under the ROC curves (AZ) were analyzed by pairwise comparison.

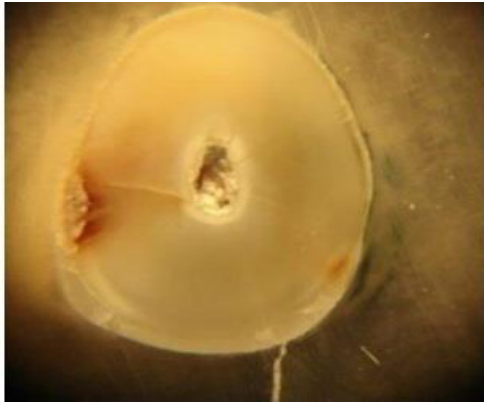


Figure 3. Microscopic view of the sectioned tooth

### Results

In this in vitro study, 80 proximal surfaces of 40 extracted premolars were assessed. According to histological analyses, 43 (53.75%) proximal surfaces were caries free. In contrast, 37 proximal surfaces (46.25%) had caries with different depths, i.e., caries in the enamel, DEJ, and dentin were found in 5, 2, and 30 cases, respectively. Each observer re-evaluated the images with a two-week interval. The Wilcoxon Signed-Rank statistical test was used to determine intra- and

inter-observer agreement. There was no significant difference at the 95% confidence interval. Pairwise comparisons between Az values revealed no significant differences between the color and black and white images ( $P = 0.973$ ). Table 1 presents Az values regardless of caries depth. Figure 4 shows the ROC curve for the images before and after the application of the pseudocolor filter. Tables 2 and 3 summarize Az values based on caries depth.

Table 1. Mean of areas under the ROC curve

Image modality	Area	Confidence Interval Upper Bound
Grayscale images	0.533	0.660
Color images	0.559	0.686

Table 2. The area under the ROC curve for black and white images based on caries depth

Depth of caries	Area	Confidence Interval Upper Bound
No caries	0.525	0.652
Enamel	0.513	0.640
DEJ	0.500	0.627
Dentin	0.563	0.689

Table 3. The area under the ROC curve for color images based on caries depth

Depth of caries	Area	Confidence Interval Upper Bound
No caries	0.563	0.689
Enamel	0.513	0.640
DEJ	0.475	0.602
Dentin	0.575	0.701

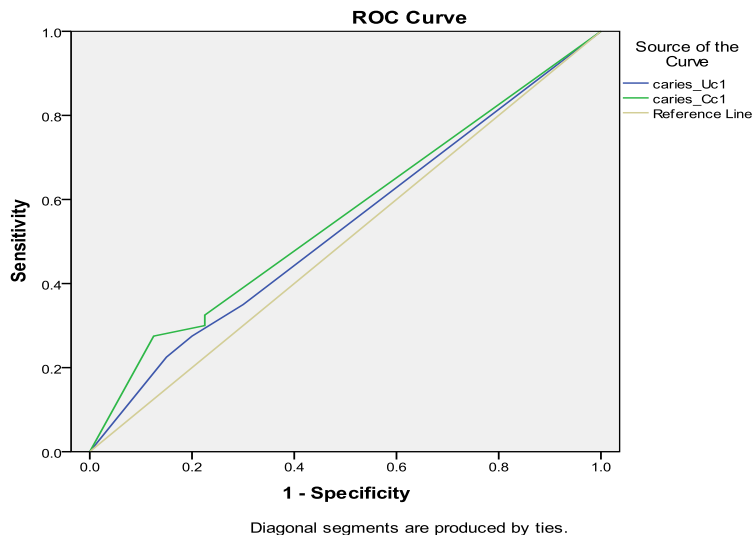


Figure 4. Receiver operating characteristic (ROC) curves for grayscale and color images.

## Discussion

While radiography is still a standard diagnostic method for the detection of proximal caries, conventional films are gradually being superseded by digital radiography.<sup>(13)</sup> Software programs designed for these digital systems provide the possibility to modify different image properties such as brightness and contrast, produce pseudo three-dimensional images (embossing), change the contrast (reverse contrast) and apply pseudocolor filters (false coloring).

The present study used a pseudocolor filter to detect proximal caries. The human visual system is theoretically more sensitive to colors than to shades of gray.<sup>(1)</sup> In other words, it can discriminate between colors better than between shades of gray. Therefore, detection accuracy was expected to be higher with color images than black and white radiographs.<sup>(14)</sup> However, our study could not establish a significant difference in caries detection between grayscale and color images. Similar findings about the efficacy of pseudocolor filters in the detection of proximal caries were reported by Zangoeei et al. and Shi et al. They used the CCD sensors (RVG U16, Trophy) and PSP (Digora® Optime) and CCD (Dixi®) sensors, respectively.<sup>(13,15)</sup> To evaluate diagnostic accuracy of secondary caries using the CMOS sensor and application of pseudocolor filters, Depra et al. found that the use of different radiographic enhancement filters did not improve diagnosis of secondary caries.<sup>(16)</sup>

Despite the limited number of studies on the efficacy of pseudocolor filters in the detection of proximal caries, it seems that the algorithm of the software cannot enhance the efficacy of radiographic systems in caries detection. Nevertheless, further studies are warranted to confirm these findings about the efficacy of such software programs.

Li et al. found no significant difference between grayscale and color images in determining marginal bone level in patients with chronic periodontitis.<sup>(17)</sup> In contrast, Scarfe et al. used CCD sensors (Visualix® 2, Gendex Dental Systems, USA) and found that color images have lower accuracy in estimating periradicular lesion dimensions.<sup>(18)</sup>

Many researchers have proposed the use of ROC analysis to assess various caries detection meth-

ods.<sup>(6,8,10,16,19-21)</sup> The area under the ROC curve (Az value) provides the information required for measuring the accuracy of diagnostic systems. In the present study, ROC curves were drawn for both grayscale and color images. Although there were no significant differences, the results showed slightly higher Az values in the absence of caries and dentinal caries than in the presence of enamel and DEJ caries. Likewise, Castro et al. reported dentinal caries to have higher Az values compared to enamel lesions.<sup>(7)</sup>

In the present study, the Az values in cases of enamel caries were the same in black and white and color images. In cases of dentinal caries, the Az values were a little higher in color images compared to black and white images. In a study conducted by Shi et al., the Az values of enamel and dentin caries did not have much difference in different digital systems in black and white and color images.<sup>(15)</sup>

Thus, according to the previous researches and the present study, pseudocolor filters seem ineffective in improving the accuracy of proximal caries detection in digital images produced by any type of intraoral digital system.<sup>(13,15,16)</sup> Moreover, the performance of such filters does not appear to depend on lesion depth. Nevertheless, since pseudocolor filters do not result in the loss of any diagnostic information, they can be used by clinicians to produce alternatives to black and white digital images.

As the histological sectioning of teeth is not possible in vivo, research on the efficacy of pseudocolor filters (like the present study) has been generally conducted in vitro.<sup>(13,15,16)</sup> In order to obtain the gold standard in caries detection, most studies have examined extracted teeth. Meanwhile, Li et al. compared the accuracy of caries detection by digital radiographs in vitro and in vivo.<sup>(22)</sup> Since they found no significant differences in Az values obtained from the two methods, the diagnostic accuracy of in vitro studies on proximal caries can represent the diagnostic accuracy in real clinical conditions.

## Conclusion

Both grayscale and color images had similar accuracy in the detection of proximal caries and did not depend on caries depth. However, human visual system is theoretically more sensitive to colors than to shades of gray and color images

can facilitate diagnosis. Therefore, clinicians interested in novel technologies can use pseudocolor filters to detect proximal caries.

The authors are grateful to Ms. Zahra Pourhabibi for providing statistical advice.

## Acknowledgement

This article was derived from the thesis of Ms. Habibeh Alimohammadi (No. 1292), Rasht School of Dentistry.

## References

1. Stuart C, White DDS, Michael J P. Oral radiology principle and interpretation. 7th ed. USA: Mosby; 2014. p.41,50, 285, 288.
2. Alkurt MT. In vitro comparison of four different dental X-ray films and direct digital radiography for proximal caries detection. *Operative dentistry* 2007; 32(5):504-509.
3. Abreu M, Mol A, Ludlow JB. Performance of RVGui sensor and Kodak Ektaspeed Plus film for proximal caries detection. *Oral Surg Oral Med Oral Pathol Oral Radiol Endod* 2001 Mar;91(3):381-5.
4. Nair MK, Nair UP. An in-vitro Evaluation of Kodak Insight and Ektaspeed Plus Film with a CMOS Detector for Natural Proximal Caries: ROC Analysis. *Caries Res* 2001; 35: 354-359.
5. Hintze H, Wenzel A, Fryderberg M. Accuracy of caries detection with four storage phosphor systems and E-speed radiographs. *Dento maxillofacial Radiology* 2002; 31: 170-175.
6. Khan EA, Tyndall DA, Ludlow JB, Caplan D. Proximal caries detection: Sirona Sidexis versus Kodak Ektaspeed Plus. *General dentistry* 2005; 28: 43-47.
7. Castro VM, Katz JO, Hardman PK, et al. In vitro comparison of conventional film and direct digital imaging in the detection of approximal caries. *Dentomaxillofac Radiol* 2007 Mar;36(3):138-42.
8. Rockenbach MI, Veeck E B, Costa NP. Detection of proximal caries in conventional and digital radiography: an in vitro study. *Stomatologia, Baltic Dental and Maxillofacial journal* 2008; 10: 115-120.
9. Peker I, Alkurt MT, Bala O, Altunkaynak B. The Efficiency of Operating Microscope Compared with unaided Visual Examination, Conventional and Digital Intraoral Radiography for Proximal Caries Detection. *Int J Dent.* 2009; 2009: 986873.
10. Senel B, Kamburoglu K, Uçok O, et al. Diagnostic accuracy of different imaging modalities in detection of proximal caries. *Dentomaxillofac Radiol* 2010;39:501-511.
11. Ulusu T, Bodur H, Odabas ME. In vitro comparison of digital and conventional bitewing radiographs for the detection of approximal caries in primary teeth exposed and viewed by a new wireless handheld unit. *Dentomaxillofac Radiol* 2010; 39:91-94.
12. Woolhiser GA, Brand JW, Hoen MM, et al. Accuracy of film-based, digital, and enhanced digital images for endodontic length determination. *Oral Surg Oral Med Oral Pathol Oral Radiol Endod* 2005; 99 : 499-504
13. Zangoeei BM, Davari A, Ezoddini AF, Rashidi Nejad MR. Efficacy of application of pseudocolor filters in the detection of interproximal caries. *J Dent Res Dent Clin Dent Prospects.* 2010 Summer;4(3):79-82. Epub 2010 Sep 16.
14. Shi X-Q, Welander U, Sallstrom P. A color coding method for radiographic images. *Image Vision Computing* 2002; 20: 761-767.
15. Shi XQ, Li G. Detection accuracy of approximal caries by black-and-white and color-coded digital radiographs. *Oral Surg Oral Med Oral Pathol Oral Radiol Endod* 2009;107:433-436.
16. Deprá Lde C, Vessoni Iwaki LC, Chicarelli M, Takeshita WM. Influence of image filters and variation in horizontal angle of incidence of x-ray beam in digital interproximal radiographs for diagnosis of secondary caries in esthetic restorations. *J Contemp Dent Pract* 2015;16(10):805-12.
17. Li G, Engström PE, Welander U. Measurement accuracy of marginal bone level in digital radiographs with and without color coding. *Acta Odontol Scand* 2007 Oct;65(5):254-8.
18. Scarfe WC, Vanessa J, Allan G, et al. In vivo accuracy and reliability of color-coded image enhancements for the assessment of periradicular lesion dimensions. *Oral Surg Oral Med Oral Pathol Oral Radiol Endod* 1999; 88:603-11.
19. Halme KH, Nilsson M, Petersson A. Effect of monitors on approximal caries detection in digital radiographs-standard versus precalibrated DICOM part 14 displays: An in vitro study. *Oral Med Oral Pathol Oral Radiol Endod* 2009; 107:716-720.
20. Nair MK, Nair UP. An in-vitro Evaluation of Kodak Insight and Ektaspeed Plus Film with a CMOS Detector for Natural Proximal Caries: ROC Analysis. *Caries Res* 2001; 35: 354-359.
21. Li G, Yoshiura K, Welander U, et al. Detection of approximal caries in digital radiographs before and after correction for attenuation and visual response. An in vitro study. *Dentomaxillofac Radiol* 2002; 31: 113-116.
22. Li G, Qu XM, Chen Y, et al. Diagnostic accuracy of proximal caries by digital radiographs: An in vivo and in vitro comparative study. *Oral Surg Oral Med Oral Pathol Oral Radiol Endod* 2010; 109: 463-467.