

Reactive Hyperplastic Lesion of Endodontic Origin Mimicking Pregnancy Tumor: A Case Report

Case Report

Fazele AtarbashiMoghadam¹, Saede AtarbashiMoghadam², Sara Bagheri³, Loghman Ahmadi⁴

¹Assistant Professor of Department of Periodontology, Dental School of Shahid Sadoughi University of Medical Sciences, Yazd, Iran.

² Assistant Professor of Department of Oral and Maxillofacial Pathology, Dental School of Shahid Beheshti University of Medical Sciences, Tehran, Iran.

³ Assistant professor of Department of Oral and Maxillofacial Pathology Guilan University of Medical Science.

⁴ Periodontist, Department of Periodontology, Faculty of Dentistry, Yasuj University of Medical Sciences, Yasuj, Iran.

Received: Oct 4, 2015

Accepted: Jan 30, 2016

Corresponding Author:

Loghman Ahmadi

Address:

Department of Periodontics, Faculty of Dentistry, Yasuj University of Medical Sciences, Yasuj, Iran

Telephone: +982166905328

Email: s.l_ahmadi@yahoo.com

Fax: +982188770644

Abstract

Introduction:

Gingiva is a common region of inflammatory and reactive lesions. Systemic conditions, including hormonal imbalance in pregnant women, may cause exaggerated response to irritations such as calculus or infection. Therefore, more accurate assessment is necessary to achieve the best decision making in the differential diagnosis and treatment of these patients. In this paper, we present a reactive hyperplastic lesion of endodontic origin (parulis) on the gingiva in a pregnant woman, which mimicking pregnancy tumor.

Key words:

•Gingival Hyperplasia •Pyogenic Granuloma •Pulpitis

Case Report

A 20-year-old pregnant woman was referred to the Department of Periodontics, Faculty of Dentistry, Shahid Sadoughi University of Medical Sciences, with a diagnosis of pregnancy tumor. She was in the sixth month of pregnancy and mentioned this lesion two months before. She had no other medical or dental history.

Her chief complaint was gingival bleeding during mastication. Intra-oral examination showed an exophytic reddish pink growth on the gingiva between the first and the second right mandibular molars (Figure 1). The lesion did not extend lingually. In periodontal examinations, there was no periodontal pocket around these teeth. The mandibular molars teeth did not have any mobility, pathologic tooth migration, or pathologic gingival recession.

A more accurate assessment showed that the lesion was pedunculated and originated from the mid-buccal of the first molar. The first molar had excessive carious lesions. Vitality test showed that the first molar was non-vital. Because there was no sinus tract, tracing was impossible. Peri-apical radiography was obtained, using lead apron, and revealed a radiolucency around the mesial and distal root, and in the furcation area, of the first molar (Figure 2). Therefore, the first differential diagnosis considered parulis (gumboil) and then pregnancy tumor. The patient was referred for endodontic treatment. After endodontic treatment, the lesion became smaller. The patient was followed-up after childbirth.

The lesion disappeared completely after one month without any periodontal or surgical intervention (Figure 3), and was filled with amalgam restoration.

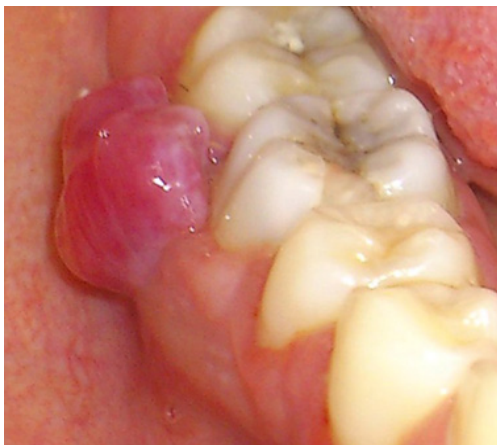

Figure 1. Clinical feature of the gingival lesion

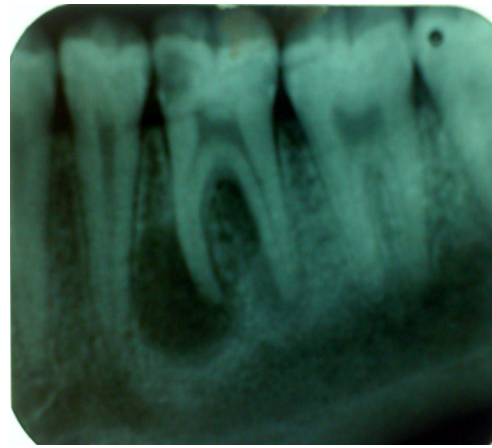


Figure 2. Periapical radiography revealed a radiolucency around the mesial and distal root and in the furcation area of first molar

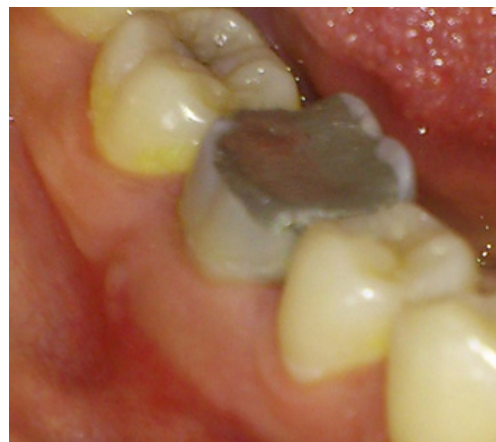

Figure 3. After parturition, the lesion completely disappeared

Discussion

The gingiva is commonly affected by non-neoplastic and neoplastic lesions. A great majority of gingival overgrowths are non-neoplastic lesions. They are either inflammatory or represent a reaction to diverse types of irritant stimuli.⁽¹⁾ Irritations such as calculus, cervical caries, trauma from occlusion, and smoking, are all found to be associated with the development of reactive gingival growths.^(2,3) Infection alone without irritation may produce sufficient irritation to activate the growth on the gingiva.⁽⁴⁾

Systemic conditions may be a contributing factor, such as pregnancy, which causes a tendency of the occurrence or rapid growth of these lesions.^(3,4)

Reactive lesions usually present on the gingiva as a singular, sessile nodule. Sizes of lesions may be various and they are almost asymptomatic unless secondarily traumatized.⁽⁵⁾ They often present as clinically diagnostic challenges

because they mimic various groups of pathologic processes. They are clinically similar but possess distinct histopathological features.⁽²⁾

When a lesion is found on the gingiva, differential diagnosis and the true origin of the lesion are important steps, since these could help to correct treatment.⁽⁶⁾

The most common inflammatory pathologic conditions in dentistry are dental abscesses. Dental abscesses are usually associated with non-vital teeth. Clinically, they may be symptomatic or asymptomatic and they commonly produce pus. Based on their way of spreading, dental abscesses may lead to osteomyelitis, cellulitis, or a parulis/fistulous tract.⁽⁵⁾

The differential diagnoses of parulis include pyogenic granuloma, pregnancy tumor, peripheral giant cell granuloma, post-extraction granuloma, and some other lesions.⁽⁷⁾ Differential diagnosis for the present case was parulis, pregnancy tumor. Parulis is caused by periapical infection, and the treatment of choice is endodontic treatment of the suspected tooth.⁽⁸⁾ In the present case, the existence of a non-vital tooth without any clinical signs of gingival inflammation and the lesion being pedunculated from the furcation area led to the decision that the lesion had an endodontic origin and parulis was the first differential diagnosis.

References

1. Carbone M, Broccoletti R., Gambino A., et al. Clinical and histological features of gingival lesions: A 17-year retrospective analysis in a northern Italian population. *Med Oral Patol. Oral Cir. Bucal.* 2012;17(4):e555-61.
2. Effiom O.A., Adeyemo W.L., Soyele O.O. Focal reactive lesions of the gingiva: An analysis of 314 cases at a tertiary health institution in Nigeria. *Niger Med. J* 2011;52(1):35-40.
3. Rana R., Ramachandra S.S., Prasad U.C., et al. Recurrent pyogenic granuloma with satellite lesion. *Cutis.* 2015;96(2):E27-30.
4. Bernick S. Growths of the gingival and palate; chronic inflammatory lesions. *Oral Surg. Oral Med. Oral Pathol.* 1948;1(11):1029-41.
5. Meiller T.F., Garber K., Scheper M. A review of common oral pathology lesions, with the focus on periodontology and implant. *J. Evid. Base Dent. Pract.* 2012;12(3):254-62.
6. Jafarzadeh H., Sanatkhan M., Mohtasham N. Oral pyogenic granuloma: a review. *J. Oral Sci* 2006;48(4):167-75.
7. Panseriya B.J., Hungund S. Pyogenic granuloma associated with periodontal abscess and bone loss—A rare case report. *Contemp. Clin. Dent.* 2011;2(3):240-4.
8. Van Dis M.L. Swellings of the oral cavity. *Dermatol. Clin.* 1996;14(2):355-70.
9. Markou E., Eleana B., Lazaros T., Antonios K. The influence of sex steroid hormones on gingiva of women. *Open Dent. J* 2009;3:114-119.
10. Gonsalves W.C., Chi A.C., Neville B.W. Common oral lesions: Part II. Masses and neoplasia. *Am. Fam. Physician* 2007;75:509-12.
11. Tabatabaei Nejad E.S., Taheri J.B., Azimi S. Frequency of gingiva pregnancy tumor in Iran (confirmed by biopsy). *J. Int. Oral Health* 2014;6(6):72-6.

Pyogenic granuloma is a type of inflammatory hyperplasia and one of the most common oral reactive lesions. This lesion has a tendency to occur on the interdental papilla.^(5,6) Pregnancy tumor is a gingival pyogenic granuloma, which develops in up to 5% of pregnancies and resolves spontaneously after parturition. Generally it appears in the second and third month of pregnancy. It has a tendency to bleeding and interfering with mastication.^(5,9,10) In the study, Tabatabaei Nejad et al. reported that the frequency of pregnancy tumors in Tehran Medical Center, Iran in 2013 was 0.22%, and they concluded the prevalence of this lesion in pregnant women was lower than in previous studies.⁽¹¹⁾

Female sex steroid hormones have been shown to directly and indirectly exert an influence on cellular proliferation, differentiation and growth in target tissues, including keratinocytes and fibroblasts in the gingiva.⁽⁶⁾ In addition, hormonal imbalance during pregnancy heightens the organism's response to irritation. Therefore, the clinical sign of disease may be exaggerated in pregnant women.⁽¹⁾

In conclusion, attention to the clinical and radiographic signs and symptoms and differential diagnosis are important for the management of the best treatment plan of a patient. It is more important in pregnant women because of the alteration in their systemic situation.